

Integrative Ayurvedic Management of Recurrent Gluteocutaneous Pyogenic Granuloma: A Case Report

KAMAL SAHU¹, POOJA SHRIVASTAV², MAGESH KIRUBAKARAN³, SAMPADA GHATBANDHE⁴

CC BY-NC-ND

ABSTRACT

Pyogenic granuloma is a rapidly proliferative vascular lesion marked by lobular capillary growth and fragile hypergranulation. While commonly small and responsive to excision, recurrent gluteocutaneous pyogenic granuloma is exceptionally rare. Recurrence after multiple debridements indicates dysregulated angiogenesis, excessive Vascular Endothelial Growth Factor (VEGF) expression, heightened inflammation, or aberrant wound remodeling. Ayurvedic evidence supports the use of anti-angiogenic, anti-proliferative and cytomodulatory interventions. This case presents a rare treatment-resistant pyogenic granuloma that responded to an integrative Ayurvedic protocol. A 38-year-old female presented with a large exophytic hypergranulated lesion on the right gluteal region that recurred despite three prior debridements. Post-debridement, an integrative Ayurvedic protocol was initiated: *Apamarga Kshara* and *Tamra Bhasma* dusting, followed by *Yashtimadhu Ghrita* dressings, oral *Yashtimadhu* tablets, and short-term intravenous antibiotics. Healing parameters including pain, discharge, granulation tissue coverage, and wound appearance were graded using established wound-assessment scales. Significant improvement appeared by Day 7, with reduction in pain and discharge and formation of healthy granulation tissue. By Day 14, pain and discharge resolved completely, and full granulation coverage was achieved. Complete healing with a healthy scar occurred by Day 45. Follow-up at 1, 3, and 6 months showed stable healing with no recurrence, a rare outcome given the lesion's prior aggressive behaviour. The observed clinical response is biologically plausible based on contemporary experimental studies suggesting anti-proliferative and angiogenesis-modulating properties of certain constituents; however, these mechanisms are not directly described in classical Ayurvedic texts and remain interpretative correlations. This rare case demonstrates that an integrative Ayurvedic protocol can successfully treat recurrent, angiogenesis-driven pyogenic granulomas unresponsive to conventional management. The outcome is supported by classical principles and modern pharmacological evidence.

Keywords: Ayurvedic therapeutics, Kshara application, Wound healing

CASE REPORT

A 38-year-old female presented with a large, exophytic, hypergranulated lesion in the right gluteal region. The patient complained of significant pain at the lesion site, particularly during sitting and movement. On assessment using the Visual Analogue Scale (VAS), the pain was graded as severe (Grade 3). The surface was irregular, friable, and intermittently bleeding. The patient denied trauma, systemic disease, or immunosuppression. On systemic examination {Cardiovascular System (CVS), Respiratory System (RS), Central Nervous System (CNS)}, no abnormality was detected.

Despite three previous surgical debridements, the lesion recurred each time, demonstrating an unusually aggressive wound phenotype. The patient reported that recurrence occurred within approximately 4-6 weeks following each of the previous debridements. Detailed operative notes from prior procedures were not available for review, and the exact surgical techniques employed could not be verified. Postoperative management reportedly included routine wound dressings; however, no documentation of advanced topical therapies such as chemical cautery, silver-based dressings, or other specialised modalities was available. The integrative Ayurvedic protocol was initiated immediately after the most recent debridement during the current presentation.

The patient had no history of diabetes mellitus, hypertension, tuberculosis, bleeding disorders, or long-term medication use.

Investigations

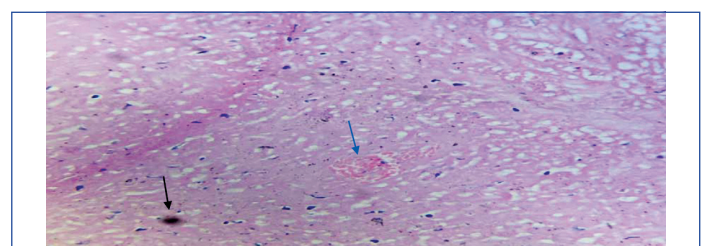
Laboratory evaluation revealed mild normocytic hypochromic anaemia, leukocytosis (15,900/cu.mm), and an elevated Erythrocyte

Sedimentation Rate (ESR) (51 mm/hr), consistent with active inflammation. Peripheral smear showed normocytic hypochromic Red Blood Cells (RBCs), leukocytosis, and adequate platelets. HIV, HBsAg, and Mantoux tests were negative, ruling out infectious or granulomatous causes.

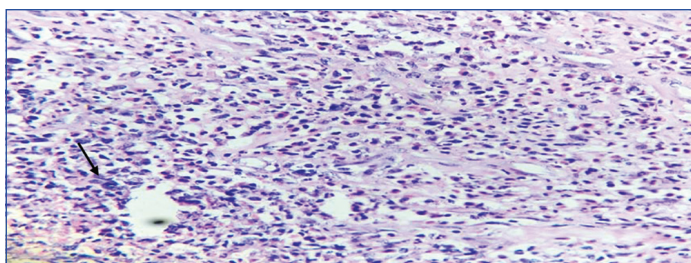
Ultrasonography (USG) of the right gluteal region showed oedema and fluid in the subcutaneous plane, with fat lobules exhibiting a cobblestone appearance, indicating inflammatory changes. The granulation tissue demonstrated good vascularity, and no focal collection or abscess was identified.

Histopathology of the excised tissue revealed multiple irregular grey-white tissue fragments measuring 5×5×2 cm, showing surface ulceration of squamous epithelium, granulation tissue, and acute on chronic inflammation with extensive eosinophilic infiltration, confirming hypergranulated inflammatory tissue consistent with pyogenic granuloma [Table/Fig-1,2].

The provisional diagnosis was recurrent hypergranulated inflammatory lesion, and the final diagnosis was recurrent pyogenic granuloma confirmed by histopathological evaluation.



[Table/Fig-1]: Histopathology showing ulcerated squamous epithelium (black arrow) and granulation tissue (blue arrow) (H & E stain, 10× magnification).



[Table/Fig-2]: Histopathology showing eosinophilic infiltration (black arrow) (H & E stain, 40x magnification).

Therapeutic Intervention

Given the repeated recurrence, an integrative Ayurvedic protocol was initiated immediately after the final debridement. Topically, Apamarga Kshara (300 mg) and Tamra Bhasma (300 mg) were gently dusted over the lesion. This was followed by Yashtimadhu Ghrita dressings applied twice daily to support epithelial regeneration and reduce inflammation. Systemic support included oral Yashtimadhu tablets (500 mg) twice daily for internal wound modulation and intravenous Ceftriaxone 1g twice daily for three days for infection control. Together, this combined regimen targeted pathological granulation, controlled local microbial burden, and promoted organised and sustained wound healing.

Apamarga Kshara provides Ksharana-Lekhana effects for chemical debridement and hypergranulation correction. Experimental studies have demonstrated anti-proliferative effects of *Achyranthes aspera* in certain cancer cell models; however, its role in pyogenic granuloma or wound-healing contexts has not been directly investigated. Therefore, any proposed anti-proliferative effect in this case remains hypothetical and requires disease-specific validation [1]. Tamra Bhasma has been structurally characterised in prior studies as containing nanocrystalline copper oxide using SEM, TEM, and XRD analyses. However, structural characterisation alone does not establish bioavailability, tissue penetration, or specific molecular effects following topical application. Therefore, any potential angiogenesis-modulating effect in this case remains hypothetical and requires dedicated pharmacological investigation [2]. Certain engineered copper-based nanoparticles have demonstrated VEGF-modulating effects in experimental models; however, these materials are structurally and functionally distinct from Tamra Bhasma. Therefore, direct extrapolation of such findings to traditional preparations is not justified without specific mechanistic studies [3]. Pyogenic granulomas show marked VEGF overexpression, reinforcing the need for angiogenesis-modulating therapy [4]. Anti-angiogenic natural products also suppress pathological vessel formation [5]. Angiogenesis plays a role in various pathological conditions; however, therapeutic outcomes in malignant neoplasms such as glioma cannot be directly extrapolated to benign vascular proliferative lesions. Therefore, any proposed angiogenesis-modulating effect in this case remains speculative and requires disease-specific investigation [6]. *Yashtimadhu Ghrita* enhances epithelialisation, collagen stabilisation, and anti-inflammatory healing [7,8].

Grading Criteria for Pain, Discharge, Granulation, and Wound Healing.

Pain (Visual Analogue Scale - VAS) [9]- Grade 0: No pain (VAS score of 0), Grade 1: Mild pain (VAS score of 1-4), Grade 2: Moderate pain (VAS score of 5-8), Grade 3: Severe pain (VAS score of 9-10).

Wound Discharge [10] - Grade 0: No discharge, Grade 1: Mild discharge that wets one gauze pad, Grade 2: Moderate discharge that wets two gauze pads, Grade 3: Profuse discharge that wets more than two gauze pads.

Healing (Southampton wound Grading System) [10]- Grade 0: Completely healed wound with a healthy scar, Grade 1: Clean wound without slough or discharge, Grade 2: Partially healed

wound with healthy granulation tissue, Grade 3: Wound showing signs of discharge.

Granulation Tissue Coverage [11] - Grade 0: No granulation tissue present, Grade 1: Granulation tissue covering one quarter of the wound area, Grade 2: Granulation tissue covering half of the wound area, Grade 3: Granulation tissue covering two-thirds of the wound area, Grade 4: Granulation tissue covering the entire wound area.

OUTCOME MEASURES

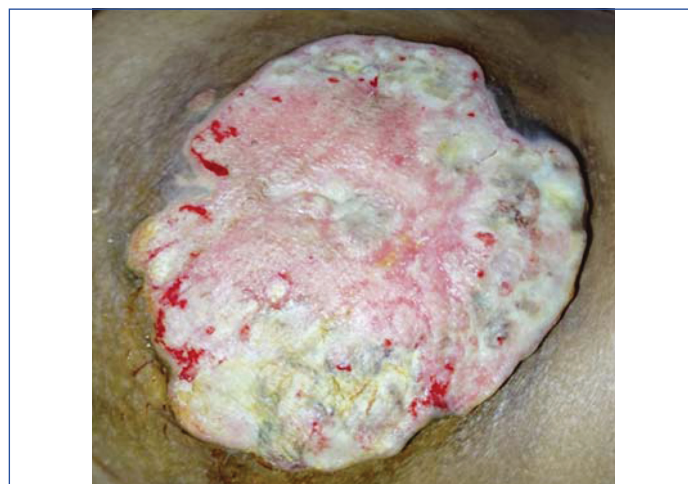Pain was assessed using the VAS. Wound outcome and healing were evaluated using the Southampton Wound Grading System and granulation tissue coverage grading scale, as described in the assessment criteria.

The patient showed rapid improvement following treatment. By Day 7, pain decreased from severe to mild, discharge reduced from Grade 3 to Grade 2, and healthy granulation appeared. By Day 14, both pain and discharge resolved, and full granulation coverage was present. By Day 45, the wound healed completely with a healthy scar [Table/Fig-3]. Improvements correlate with anti-proliferative actions of Apamarga Kshara [1], nanocrystalline Tamra modulation [2], and anti-angiogenic copper nanoparticle parallels [3]. VEGF-driven pathology of pyogenic granuloma [4] also explains the dramatic response. This healing pattern, followed by six months of recurrence-free stability, is exceptionally rare in lesions resistant to repeated debridements.

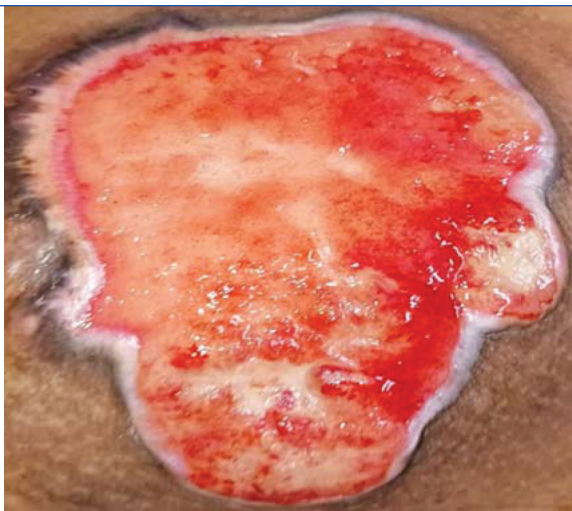
Time point	Pain (VAS)	Discharge (Southampton Grade)	Granulation tissue coverage	Clinical observation
Baseline	Grade 3 (Severe)	Grade 3	Minimal / unhealthy granulation	Painful lesion with active discharge
Day 7	Grade 1 (Mild)	Grade 2	Healthy granulation initiating	Reduced discharge and improved wound bed
Day 14	Grade 0 (None)	Grade 0	Complete granulation coverage	No pain or discharge
Day 45	Grade 0	Grade 0	Fully epithelialised	Complete healing with healthy scar
6 Months Follow-up	Grade 0	Grade 0	Stable healed scar	No recurrence

[Table/Fig-3]: Clinical outcome assessment during follow-up.

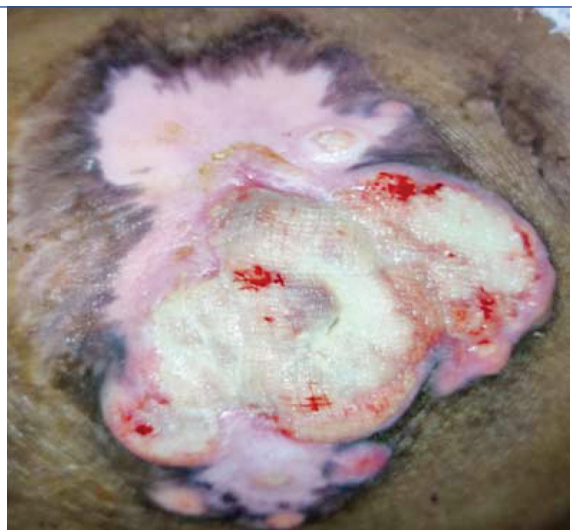Initial presentation showed an undermined wound edge with slough [Table/Fig-4]. By Day 7, healthy granulation tissue formation was observed [Table/Fig-5]. Progressive healing was noted by Day 30 with partial epithelialisation [Table/Fig-6], and complete wound healing with a healthy scar was achieved by Day 45 [Table/Fig-7].



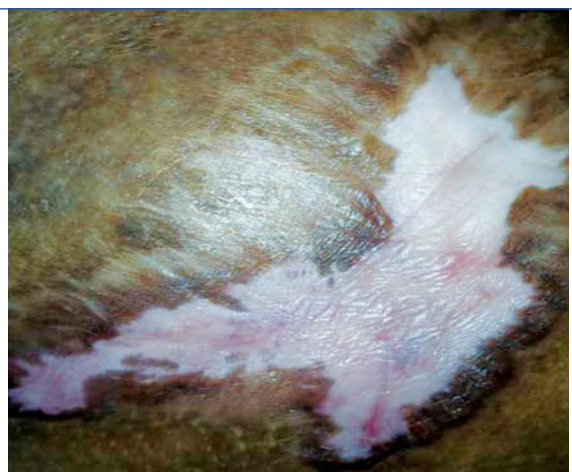[Table/Fig-4]: Day-1 showing undermined wound edge with slough.



[Table/Fig-5]: Showing healthy wound edge with slough. Granulation tissue formation.



[Table/Fig-6]: Day-30 showing partial epithelialisation.



[Table/Fig-7]: Day-45 showing complete wound healing with epithelialisation and a healthy scar.

Follow up: Follow-up at 1, 3, and 6 months showed complete healing, no hypergranulation, no discharge, and no recurrence. The long-term stability is notable, given the aggressive pathology. Anti-VEGF and anti-proliferative parallels support the durability of this integrative approach [3,5,6].

DISCUSSION

Pyogenic granuloma is a benign vascular lesion; however, its presentation as a large, recurrent, hypergranulated gluteocutaneous mass is exceptionally rare. Recurrence after multiple debridements is unusual and typically reflects persistent inflammatory triggers,

impaired wound remodeling, or dysregulated angiogenesis [12]. In this case, the lesion recurred despite three debridements, indicating an unusually resistant hypergranulation process requiring an integrative therapeutic approach.

The Ayurvedic protocol used here demonstrated remarkable efficacy in a presentation where conventional treatments repeatedly failed. *Apamarga Kshara* provides potent Ksharana–Lekhana actions that chemically debride hypergranulated tissue and regulate abnormal cellular proliferation. This is supported by modern evidence showing that its botanical source, *Achyranthes aspera*, possesses significant anti-proliferative activity, inhibiting cancer cell growth and promoting apoptosis [1]. *Tamra Bhasma*, long recognised in Ayurveda for its Lekhana and antimicrobial effects [13], has now been validated scientifically through advanced analyses confirming that it exists in a nanocrystalline copper oxide form. These nano-sized particles exhibit enhanced catalytic, antimicrobial, and tissue-interactive properties, explaining their rapid effect in reducing hypergranulation and stabilising wound morphology [2].

A central mechanism in pyogenic granuloma pathogenesis is excessive angiogenesis. Bragado R et al., (1999) reported increased VEGF expression in pyogenic granulomas, suggesting a role of angiogenesis in their pathogenesis. However, VEGF levels were not assessed in the present case; therefore, any interpretation regarding angiogenic modulation remains speculative [4]. This aligns with the rapid expansion, friability, and recurrent hypergranulation observed in the present case. Ayurvedic interventions such as Kshara and Tamra Bhasma possess cauterising and vascular-modulating effects, which may counteract VEGF-driven angiogenesis—an insight supported by modern anti-angiogenic research.

Sagar SM et al., (2006) highlighted that many natural compounds exhibit potent anti-angiogenic activity, suppressing pathological vessel formation and inflammation-driven vascular growth [5]. This parallels the potential action of *Tamra Bhasma* in modulating aberrant neovascular responses in pyogenic granuloma.

Insights from oncology also support this approach. Norden et al. (2009) demonstrated that anti-angiogenic therapies significantly modify disease progression in recurrent malignant glioma by suppressing VEGF-mediated neovascularisation [6]. Angiogenesis is recognised as a biological component in various pathological processes, including reactive vascular lesions. However, malignant tumours and benign lesions differ significantly in cellular behaviour, regulatory mechanisms, and therapeutic targets. Therefore, cross-disease comparisons should be interpreted with caution, and no direct therapeutic equivalence is implied in this case.

Finally, *Yashtimadhu Ghrita* complemented these actions by promoting epithelial regeneration, collagen stabilisation, and inflammation control, supported by its documented cytomodulatory effects [7,8]. The result was rapid healing and complete absence of recurrence over six months, an outcome that is exceptionally rare in recurrent pyogenic granuloma.

Overall, this case illustrates that an integrative Ayurvedic protocol—supported by modern anti-proliferative, anti-angiogenic, and nanocrystalline copper research—can offer a unique and highly effective therapeutic option in rare, treatment-resistant pyogenic granuloma.

Pyogenic granuloma is a benign vascular proliferative lesion often associated with trauma, irritation, or infection. Although recurrence after incomplete excision is well documented, spontaneous regression has also been reported in certain cases. Therefore, the natural history of the lesion must be considered when interpreting therapeutic outcomes.

Local wound care and maintenance of a clean, moist healing environment play a critical role in granulation and epithelialisation. It is possible that structured wound care following the most recent debridement contributed significantly to the observed improvement.

The role of infection control, even in the absence of documented microbiological testing, may also have influenced healing dynamics.

The reasons for recurrence following previous debridements remain unclear due to lack of operative records. Potential contributing factors may include incomplete excision, persistent local irritation, suboptimal wound care, or unaddressed inflammatory stimuli.

Additionally, placebo effects and the natural course of wound healing cannot be entirely excluded in a single-case observation. While the integrative intervention temporally correlated with clinical improvement, causality cannot be definitively established.

Thus, the present case should be interpreted as a hypothesis-generating clinical observation rather than proof of mechanistic efficacy.

This report represents a single observational case and therefore carries inherent limitations. The patient received surgical debridement and short-term intravenous antibiotics prior to the integrative intervention; thus, the independent contribution of antibiotics, surgical technique, structured wound care, natural wound healing, and the Ayurvedic regimen cannot be separately determined.

Prior operative records were unavailable, limiting comparison of previous surgical techniques and post-operative management. Baseline quantitative wound measurements were not serially documented, and although standardised outcome scales were used, observer bias cannot be excluded in this non-blinded case report.

No biochemical or molecular investigations were performed. Serum VEGF levels, immunohistochemical angiogenic markers, microbiological cultures, nanoparticle characterisation, bioavailability assessment, and tissue concentration analysis was not evaluated. Therefore, the proposed anti-proliferative and angiogenesis-modulating mechanisms remain hypothesis-generating and require validation through controlled clinical and experimental studies.

A key consideration in interpreting the present case is the role of infection control and standard wound management. The patient received short-term intravenous Ceftriaxone following surgical debridement, and laboratory findings showed leukocytosis and elevated ESR, indicating active inflammation or infection. Therefore, adequate infection control, surgical debridement, and structured wound care may have contributed significantly to the initial stabilisation and healing of the lesion.

It is important to acknowledge that in a single observational case, the relative contribution of antibiotics, surgical technique, wound dressing practices, natural wound maturation, and the integrative Ayurvedic interventions cannot be independently determined. These factors represent important confounding variables when interpreting treatment outcomes.

However, the patient had previously undergone three debridements with recurrence occurring within 4-6 weeks after each procedure. In contrast, the current episode demonstrated sustained

healing without recurrence during six months of follow-up after implementation of the integrative protocol. While this temporal association may suggest a possible contributory role of the Ayurvedic interventions, this observation should be interpreted cautiously and considered hypothesis-generating rather than proof of therapeutic causality.

Further controlled clinical studies with objective wound measurements, microbiological assessment, and standardised treatment protocols will be necessary to determine the independent therapeutic contribution of such integrative interventions.

CONCLUSION(S)

This case describes clinical improvement in a recurrent pyogenic granuloma following an integrative management approach. Sustained healing without recurrence at six months was observed. However, as this represents a single observational case without molecular or comparative evaluation, causality cannot be established. The findings should be interpreted as hypothesis-generating and warrant further controlled clinical and mechanistic studies to evaluate the potential role of this integrative strategy in similar cases.

REFERENCES

- [1] Subbarayan PR, Sarkar M, Impellizzeri S, Raymo F, Lokeshwar BL, Kumar P, et al. Anti-proliferative and anti-cancer properties of *Achyranthes aspera*: Specific inhibitory activity against pancreatic cancer cells. *J Ethnopharmacol.* 2010;131(1):78-82.
- [2] Singh RK, Kumar S, Aman AK, Karim SM, Kumar S, Kar M. Study on physical properties of Ayurvedic nanocrystalline Tamra Bhasma by employing modern scientific tools. *J Ayurveda Integr Med.* 2019;10(2):88-93.
- [3] Adhikari P, S Sangeetha, Martin TM, Kishore Kumar MS. Anti-angiogenic activity of theaflavin-coated copper nanoparticles through VEGF inhibition in lung cancer cells. *Int J Environ Sci.* 2025;1211-22. Available from: <https://theaspd.com/index.php/jes/article/view/8458>.
- [4] Bragado R, Bello E, Requena L, Renedo G, Texeiro E, Alvarez MV, et al. Increased expression of vascular endothelial growth factor in pyogenic granulomas. *Acta Derm Venereol.* 1999;79(6):422-25.
- [5] Sagar SM, Yance D, Wong RK. Natural health products that inhibit angiogenesis: A potential source for investigational new agents to treat cancer—Part 1. *Curr Oncol.* 2006;13(1):14-26.
- [6] Norden AD, Drappatz J, Muzikansky A, David K, Gerard M, Mcnamara MB, et al. An exploratory survival analysis of anti-angiogenic therapy for recurrent malignant glioma. *J Neurooncol.* 2009;92:149-55.
- [7] Datta HS, Mitra SK, Paramesh R, Patwardhan B. Wound healing activity of topical application forms based on Ayurveda. *Indian J Tradit Knowl.* 2011;10(1):151-54.
- [8] Madiwalar MB, Pradeep SS, Hiremath RR, Killedar RS. Wound healing efficacy of a novel Ayurveda formulation. *J Ethnopharmacol.* 2022;284:114776.
- [9] Haefeli M, Elfering A. Pain assessment. *Eur Spine J.* 2006;15(Suppl 1):S17-S24.
- [10] Choudhary N, Soni P, Narode S, Swarnkar M. A randomized controlled clinical study of Karanjadhya Ghrita on acute wounds with special reference to its wound healing properties. *Int J Ayu Pharm Res.* 2015;3(4):01-07.
- [11] Perez D, Bramkamp M, Exe C, von Ruden C, Ziegler A. Modern wound care for the poor: A randomized clinical trial comparing vacuum system with conventional saline-soaked gauze dressings. *Am J Surg.* 2010;199(1):14-20.
- [12] Cieza-Díaz ED, Blanco CC, Heffernan JA, Ochaíta PL. Facial involutive tumors: A case of tumor-like eosinophilic granuloma of the skin. *Indian J Dermatol Venereol Leprol.* 2016;82:87-89.
- [13] Sharma A, Sharma P. *Sushruta Samhita. Vol I. Varanasi: Chaukhamba Surbharati Prakashan; 2001. Sutrasthana, Chapter 11, Verse 7. p.46.*

PARTICULARS OF CONTRIBUTORS:

1. Postgraduate Scholar, Department of Shalya Tantra, Mahatma Gandhi Ayurved College Hospital and Research Centre, Wardha, Maharashtra, India.
2. Associate Professor, Department of Shalya Tantra, Mahatma Gandhi Ayurved College Hospital and Research Centre, Wardha, Maharashtra, India.
3. Postgraduate Scholar, Department of Shalya Tantra, Mahatma Gandhi Ayurved College Hospital and Research Centre, Wardha, Maharashtra, India.
4. Postgraduate Scholar, Department of Shalya Tantra, Mahatma Gandhi Ayurved College Hospital and Research Centre, Wardha, Maharashtra, India.

NAME, ADDRESS, E-MAIL ID OF THE CORRESPONDING AUTHOR:

Kamal Sahu,
Room No. 13, Shalya Tantra OPD, Mahatma Gandhi Ayurved College Hospital and Research Centre, Salod (H), Wardha-442001, Maharashtra, India.
E-mail: sahukamal9669@gmail.com

AUTHOR DECLARATION:

- Financial or Other Competing Interests: None
- Was informed consent obtained from the subjects involved in the study? Yes
- For any images presented appropriate consent has been obtained from the subjects. Yes

PLAGIARISM CHECKING METHODS: [Jan H et al.]

- Plagiarism X-checker: Dec 19, 2025
- Manual Googling: May 02, 2026
- iThenticate Software: May 05, 2026 (3%)

ETYMOLOGY: Author Origin

EMENDATIONS: 7

Date of Submission: **Dec 10, 2025**

Date of Peer Review: **Jan 15, 2026**

Date of Acceptance: **May 07, 2026**

Date of Publishing: **Aug 01, 2026**